

ORIGINAL RESEARCH ARTICLE

EVALUATION OF IMAGE QUALITY IN CERVICAL SPINE LATERAL RADIOGRAPHS S Shrestha¹, S Maharjan², U Khanal³, M Humagain³

¹ MRI Tech (B.Sc.MIT), Kathmandu Neuro Center and Polyclinic, Baghbazaar, Kathmandu, Nepal

² Department of Radio-diagnosis & Medical Imaging, Universal College of Medical Sciences, Bhairahawa, Nepal

³ Department of Radiology and Imaging, Tribhuvan University Teaching Hospital, Kathmandu, Nepal

*Correspondence to: Surendra Maharjan, Department of Radio-diagnosis & Medical Imaging, Universal College of Medical Sciences, Bhairahawa, Nepal.
E-mail: suren634634@gmail.com.

ABSTRACT

In diagnostic radiography, cervical lateral spine x-ray is common radiographic examination among imaging of cervical spine. Thus, it is important to show entire anatomical structure, adequate penetration, soft tissue of neck and bony detail. This study attempts to quantify the quality of cervical spine radiographs by evaluating the quality of depiction of the anatomical and physical details. In this cross-sectional study, about 188 cases of cervical spine lateral radiographs were collected for study over the three months of period. Nine image criteria i.e. anatomical coverage, soft tissue visualization, C7/T1 junction, sharp bony detail, proper chin raise, artifact, density, patient rotation and collimation were followed and tabulated. Obtained data were analyzed using in SPSS v.20 software and shown in frequency, percentages, bar diagrams and graphs. Among 188 patients, about 23.4% cervical radiographs met all image criteria but remaining 76.6% did not meet these criteria due to no anatomical coverage (33.5%), no proper chin raise (46.3%), artifact (13.3%), patient rotation (50%) and no collimation (33.5%). It is difficult to perform good quality cervical radiograph according to European guidelines¹⁴. To a great extent the quality of cervical radiographs depends upon skill of radiographer, equipment condition (x-ray machine, CR reader) and co-operation of patients. This is always a challenge for radiographer and technologist.

Key words: Cervical spine radiography, Image criteria, Image quality, Lateral radiograph.

DOI: <http://dx.doi.org/10.3126/jcmc.v6i1.16652>

INTRODUCTION

Conventional radiography contributes for majority of cervical spine examinations in the radiology department. The films should have proper image quality and other physical features for better visualization. The radiographer will limit the thousands of technical, positioning and patient options to one set of factors designed to produce a diagnostic radiographs as preferred option.¹ Institutions may have specific criteria for accepting radiographs. Antero-posterior (AP) and Lateral (lat) projection of the cervical spine is commonly practiced. Supplementary oblique (obl) views are occasionally helpful to show the intervertebral foramina. The cervical spine, also referred to as C-spine, is the "most mobile portion of the vertebral column and the least supported".² The lateral radiograph of cervical spine must demonstrate all

the anatomical coverage. The head should be flexed or extended such that the angle of the mandible is not superimposed over the upper anterior cervical vertebra or the occipital bone does not obscure the posterior arch of the atlas. In order to demonstrate the lower cervical vertebra, the shoulders should be depressed. The whole of the cervical spine should be included, from the atlanto-occipital joints to the top of the first thoracic vertebra. The mandible or occipital bone does not obscure any part of the upper vertebra. Angles of the mandible and the lateral portions of the floor of the posterior cranial fossa should be superimposed. Soft tissues of the neck should be included. The contrast should produce densities sufficient to demonstrate soft tissue and bony detail. The common faults during cervical spine lateral radiography is failure to demonstrate

C7/T1 and the main remedy is if the patient cannot depress the shoulders, even when holding weights, then a swimmers' projection should be considered.^{2,3}

METHODOLOGY

A cross-sectional and descriptive study was carried out in Radiology Department of Tribhuvan University Teaching Hospital (TUTH) for a period of three months from 25th August to 24th October 2014. About 188 cases of cervical spine lateral radiographs were collected within this duration. These radiographs were performed in upright erect position by using Shimadzu x-ray machine with capacity 150 kV and 700 mA. The x-rays were performed in kV ranges from 90-110 and mAs ranges 15-60 using Computed Radiography (CR) image receptor (AGFA Company) of standard speed. The size of image receptor was 10"x12" with use of vertical stand. These x-rays were processed in AGFA CR 30 reader.

The quality of all collected cervical spine radiographs were evaluated under nine criteria such as anatomical coverage, soft tissue visualization, C7/T1 junction, sharp bony detail, proper chin raise, artifact, density, patient rotation, collimation and all correct (met all mentioned above criteria). Each criterion was classified into Yes (Y) and no (N) category. The data sets were tabulated and analyzed using SPSS v.20 software. Descriptive statistics was used to analyze data.

RESULTS

A total of 188 (93 male and 95 female) cervical spine radiographs was evaluated based on standard image criteria (anatomical coverage, soft tissue visualization, C7/T1 junction, sharp bony detail, proper chin raise, artifact, density, patient rotation and collimation). About 23.4% cervical radiographs met all image criteria but remaining 76.6% did not

meet these criteria due to no anatomical coverage (33.5%), no proper chin raise (46.3%), artifact (13.3%), patient rotation (50%) and no collimation (33.5%). All correct criteria evaluation showed 23.4% radiographs were correct and 76.6%.

Table No. 1: Showing evaluation criteria

Evaluation criteria	Yes	%	No	%
Anatomical coverage	125	66.5	63	33.5
Soft tissue visualization	188	100	-	-
C7/t1 junction	125	66.5	63	33.5
Sharp bony detail	188	100	-	-
Proper chin raise	101	53.7	87	46.3
Artifact	25	13.3	163	86.7
Density	188	100	-	-
Patient rotation	94	50	94	50
Collimation	125	66.5	63	33.5

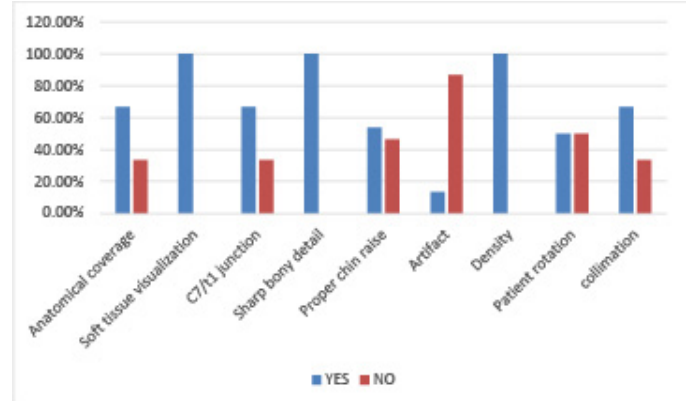


Figure No. 1: Bar diagram showing different evaluation criteria

Table No. 2: Distribution according to gender

S.N.	Male	Female	Total
Frequency	93	95	188

Table No. 3: Different criteria and their percentage evaluated

S.N.	Criteria	Yes		NO		Total	
		Numeric	(%)	Numeric	(%)	Numeric	(%)
1	Proper chin raise	101	53.7%	87	46.3%	188	100%
2	No artifact	163	86.7%	25	13.3%	188	100%
3	No patient rotation	94	50%	94	50%	188	100%
4	Collimation	125	66.5%	63	33.5%	188	100%

DISCUSSION

Among 188 patients, only 23.4% of the total study cases met all nine criteria of image quality. However, 76.6% was incorrect due to one or more than one reasons mentioned in the nine criteria of the study. Incorrect cervical spine radiographs were unacceptable for reporting and required repetition. Due to repetition, there was increased radiation dose to patients, increased workload and huge economic loss. The errors in anatomical coverage, chin raise, artifact and massive rotation altered the diagnosis. These errors were too high for acceptance. The major fault was due to patient rotation (50.0%), no proper chin raise (46.3%), no collimation (33.5%), no coverage (33.5%) and minor cause was artifacts (13.3%). The error was due to inappropriate instruction given to patients by radiographer or due to the obese patients. The rotation error is because of improper positioning of the patient. These errors might either be due to overload of patients or due to the negligence of radiographers while giving instructions. It might also be due to lack of co-operation between patient and the radiographer. It is very essential to give proper instructions to the patient as radiographers are the concerned and authorized personnel for this. It is their sole duty to improve the quality of images and aid in the diagnosis by providing clear views of the underlying diseases. These errors however can be corrected by radiographer himself by careful positioning of patient and giving adequate instruction to the patient being radiographed before the examination. Evaluation of specific features in cervical spine radiograph was found to be feasible and practicable for routine use¹¹. While it was normally easy to say that one image was better than the other. It was difficult to define which feature influence this decision. It was clear from the study that all the criteria which include different aspects; correlate fairly well with the quality of radiographs. Thus, image quality research should be carried out more in the imaging department to improve overall qualities of image and the imaging department as well.

According to European Guidelines for image quality in cervical spine radiograph- The C1 through C-7 cervical vertebral bodies, intervertebral disc spaces, articular pillars, spinous processes, and apophyseal joints should be demonstrated. The junction of C1 to

T1 should be seen; otherwise additional views such as Swimmer's view should be obtained. The rami of the mandible should not superimpose C1 to C2. No rotation can be evidenced by superimposition of both rami of mandible, both side apophyseal joints, and posterior borders of the vertebral bodies. For extension view, spinous processes should be in close proximity. For flexion view, spinous processes should be well separated. Optimal exposure should clearly demonstrate soft tissues as well as margins of air column and bony vertebrae.⁴

Michelle Keating & Stuart Grange, 2011 conducted a study regarding image quality in anteroposterior cervical spine radiograph. They observed a significant reduction in dose when the non-grid technique was compared to stationary or moving grid techniques. A statistically significant reduction in image contrast, sharpness and acceptability was also seen in the non-grid compared to grid techniques. These results showed evidence of significantly greater image quality in the presence of either a moving or stationary grid in the lamb model. As such they support the continued use of scatter rejection methods such as the anti-scatter grid in AP radiography of the human cervical spine, to optimize radiographic image quality in this critical structure.⁵

Leckie et al. evaluated the computed radiography images of 100 randomly selected traumatic cervical spine series. They reviewed on the laser printed hardcopy and 2K monitor soft copy images. In addition to the cervical vertebrae, the cervico-thoracic vertebral body interface must be recognized for a lateral c-spine image to be acceptable. The level of visualization of the spine was on average, 1/2 vertebral body better on the monitor than the hardcopy image. In 8% of cases, this improved visualization allowed clearance of the lateral cervical spine thereby expediting patient care in this critical area. This presentation will cover the quality of images and techniques to improve the success rate for clearing the cervical spine.⁶

Chand et al, 2013 evaluated the image quality of chest radiographs and their compliance with the European Guidelines. They noticed different values based on standard image criteria (categorized into anatomical coverage, arrested inspiration, adequate penetration, no rotation, scapula out of lungs field). The study resulted in 52.3% radiographs being

correct and 47.7% being incorrect. The causes of unacceptable radiographs were found depending on the skill of the radiographer and machine status.⁷

Owusu-Banahene et al, 2014 analyzed the rejected films which indicated 14.1% reject rate. The highest reject rate was for cervical spine ($57.1 \pm 0.7\%$) and the lowest was for lumbar spine ($7.7 \pm 0.5\%$). The major factors contributing to film rejection were found to be over exposure and patient positioning in cervical spine examinations.⁸

CONCLUSION

Although the newer imaging modalities like CT and MRI have supplanted the frequency of cervical spine radiographs, it is being performed today as well in developing countries as a baseline test for further clinical evaluation and also due to its simplicity, cost effectiveness, readily availability and time saving properties. Cervical spine lateral radiograph is the primary modality of imaging of cervical spine. It is simple, readily available and cost effective imaging technique. But it is difficult to perform good image quality according to European guidelines. Our study showed only the 23.4% of cervical spine radiographs were correct but remaining 76.6% of poor quality. These errors however can be corrected by radiographer himself by careful positioning of patient and giving adequate instruction to the patient. To a great extent the quality of cervical spine radiographs depends upon skill of radiographer, equipment condition and performance (x-ray machine, CR reader) and co-operation of patients. This is always a challenge for radiographer and radiologic technologist. Various researches need to be performed to improve the quality of radiographs thereby enhancing the diagnostic accuracy and to minimize the radiation dose to patients.

REFERENCES

1. Steven B. Dowd EdD RT, Bettye G. Wilson MAEd RT(R) RDMS, Encyclopaedia of Radiographic Positioning, 1995.
2. A. Stewart Whitley, Charles Sloane et.al, Clark's positioning radiography, 12th Edition, 2005.
3. Merrill's Atlas of Radiographic positioning and Radiological Procedure. 11th edition, volume 1; Mosby 2007;530.
4. European Commission, European guidelines on quality criteria for diagnostic radiographic images, Brussels, 1996.
5. Michelle Keating, Stuart Grange. Image quality in the anteroposterior cervical spine radiograph; Radiography: An international Journal of Diagnostic Imaging & Radiation Therapy; The Society of Radiographers, Feb 2011.
6. Robert GL, Monet RS, Lawrence C, Fred G, Meyers CA, et al. Evaluation of traumatic lateral cervical spine computed radiography images: quality control acceptability of images for clinical diagnosis, hardcopy versus high-resolution monitors, Proc. SPIE 1897, Medical Imaging 1993: Image Capture, Formatting, and Display, 128 (June 30, 1993); doi: 10.1117/12. 146959.
7. Chand RB, Thapa N, Pokhrel GB, et al. Evaluation of image quality in chest radiographs; Journal of Institute of Medicine 2013;35(1):50-52.
8. J. Owusu-Banahene, Darko EO, Hasford F, Addison EK, J. Asirifi O. Film reject analysis and image quality in diagnostic Radiology Department of a Teaching Hospital in Ghana; The Egyptian Society of Radiation Sciences and Applications;doi:10. 1016/j.jrras.2014.09.12.